The diagnosis and management of acute traumatic diaphragmatic injury: A Western Trauma Association clinical decisions algorithm

Morgan Schellenberg, MD, Raul Coimbra, MD, PhD, Chasen A. Croft, MD, Charles Fox, MD, Jennifer Hartwell, MD, Natasha Keric, MD, Manuel Lorenzo, MD, MBA, Matthew J. Martin, MD, Gregory A. Magee, MD, MSc, Laura J. Moore, MD, Alica R. Privette, MD, Kevin M. Schuster, MD, Ronald Tesoriero, MD, Jordan A. Weinberg, MD, *and* **Deborah M. Stein, MD, MPH***, Los Angeles, California*

CONTINUING MEDICAL EDUCATION CREDIT INFORMATION

Accreditation

In support of improving patient care, this activity has been planned and implemented by CineMed and the American Association for the Surgery of Trauma. CineMed is jointly accredited by the Accreditation Council for Continuing Medical Education (ACCME), the Accreditation Council for Pharmacy Education (ACPE), and the American Nurses Credentialing Center (ANCC), to provide continuing education for the healthcare team.

AMA PRA Category 1 Credits™

CineMed designates this enduing material for a maximum of 1 *AMA PRA Category 1 Credit(s)™*. Physicians should claim only the credit commensurate with the extent of their participation in the activity.

JOINTLY ACCREDITED PROVIDER™
INTERPROFESSIONAL CONTINUING EDUCATION

Objectives

After reading the featured articles published in the *Journal of Trauma and Acute Care Surgery*, participants should be able to demonstrate increased understanding of the material specific to the article. Objectives for each article are featured at the beginning of each article and online. Test questions are at the end of the article, with a critique and specific location in the article referencing the question topic.

Disclosure Information

In accordance with the ACCME Accreditation Criteria, CineMed must ensure that anyone in a position to control the content of the educational activity (planners and speakers/authors/discussants/moderators) has disclosed all financial relationships with any commercial interest (termed by the ACCME as "ineligible companies", defined below) held in the last 36 months (see below for definitions). Please note that first authors were required to collect and submit disclosure information on behalf all other authors/contributors, if applicable.

Ineligible Company: The ACCME defines an "ineligible company" as any entity producing, marketing, selling, re-selling, or distributing health care goods or services used on or consumed by patients. Providers of clinical services directly to patients are NOT included in this definition.

Financial Relationships: Relationships in which the individual benefits by receiving a salary, royalty, intellectual property rights, consulting fee, honoraria, ownership interest (e.g., stocks, stock options or other ownership interest, excluding diversified mutual funds), or other financial benefit. Financial benefits are usually associated with roles such as employment, management position, independent contractor (including contracted research), consulting, speaking and teaching, membership on advisory committees or review panels, board membership, and other activities from which remuneration is received, or expected.

Conflict of Interest: Circumstances create a conflict of interest when an individual has an opportunity to affect CME content about products or services of a commercial interest with which he/she has a financial relationship.

The ACCME also requires that CineMed manage any reported conflict and eliminate the potential for bias during the session. Any conflicts noted below have been managed to our satisfaction. The disclosure information is intended to identify any commercial relationships and allow learners to form their own judgments. However, if you perceive a bias during the educational activity, please report it on the evaluation. All relevant financial relationships have been mitigated.

AUTHORS/CONTRIBUTORS

Morgan Schellenberg, Raul Coimbra, Multiple Academic Medical Center/Alexian Pharmaceuticals/ CSL Behring, Honoraria/Grant money, Visiting Professorship/Clinical trial, Sharon Gautschy. Chasen A. Croft, CLR Medical, Speaker fee, Speaker, Sharon Gautschy. Charles Fox, Humacyte/ Adams Conty/Prytime Medical/Wolters Kluwer, Consulting fee/ownership interest/Royalties, Consultant/Expert testimony/Advisory Board member/ownership/Author, Sharon Gautschy. Jennifer Hartwell, Natasha Keric, Manuel Lorenzo, Matthew J. Martin, Gregory A. Magee, WL Gore & Associates & Silk Road Medical/WL Gore & Associates & Cook Medical, Consulting fee/Honoraria, Consultant/Speaker, Sharon Gautschy. Laura J. Moore, Decisio Health Inc/Frontline Medical Technologies/Frontline Medical Technologies, Royalties/Stock, Clinical Advisory Board/Ownership, Sharon Gautschy. Alica R. Privette, Kevin M. Schuster, Ronald Tesoriero, and Jordan A. Weinberg have nothing to disclose. Deborah M. Stein, CSL Behring LLC, Honoraria/Consulting fee, Board Member/Consultant, Sharon Gautschy.

EDITOR-IN-CHIEF/DEPUTY EDITORS/ ASSOCIATE EDITORS

Conflict of Interest forms for all Journal of Trauma and Acute Care Editors have been supplied and are provided as Supplemental Digital Content (http://links.lww.com/TA/D55).

Claiming Credit

To claim credit, please visit the AAST website at http://www.aast.org/ and click on the "e-Learning/MOC" tab. You must read the article, successfully complete the post-test and evaluation. Your CME certificate will be available immediately upon receiving a passing score of 75% or higher on the post-test. Post-tests receiving a score of below 75% will require a retake of the test to receive credit.

Credits can only be claimed online

Cost

For AAST members and Journal of Trauma and Acute Care Surgery subscribers there is no charge to participate in this activity. For those who are not a member or subscriber, the cost for each credit is $25.

Questions

If you have any questions, please contact AAST at 800-789-4006. Paper test and evaluations will not be accepted.

Copyright © 2025 Wolters Kluwer Health, Inc. All rights reserved.

KEY WORDS: Diaphragm; trauma; injury; laparoscopy. (*J Trauma Acute Care Surg.* 2025;98: 621–627. Copyright © 2025 Wolters Kluwer Health, Inc. All rights reserved.)

The diaphragm is the large muscular division between the thoracic and abdominal compartments. It is the primary muscle used in respiration. Herniation of viscera can occur via a traumatic defect in the diaphragm, which may lead to complications, including visceral ischemia, perforation, and obstruction.[1]

Due primarily to the pressure differential between the positive pressure in the abdominal cavity and the negative pressure in the thoracic cavity, and from normal movement of the diaphragm that occurs during inspiration and expiration, significant injuries to the diaphragm may not heal without surgical repair. They can enlarge with time,[2] allowing for greater degrees of visceral entrapment and subsequent complications.[3] Nonetheless, there are also animal data supporting spontaneous healing of small diaphragm injuries.[4–6] Thus, even the concept that diaphragm injuries ought to be diagnosed and repaired surgically is controversial and further examination is needed to completely understand this important subject.

Acute traumatic injuries of the diaphragm occur after both blunt and penetrating trauma, with a reported incidence that varies dramatically based upon mechanism and anatomic location of injury.[7–9] Penetrating thoracoabdominal trauma comprises the majority of diaphragmatic injuries.[10] The thoracoabdomen is defined as the banded area demarcated by the nipples, the bottom of the scapulae, and the inferior aspect of the costal margins bilaterally. Penetrating diaphragmatic injuries occur predominantly following gunshot wounds as opposed to stab wounds.[11,12] This should be expected to vary regionally with differences in rates of gunshot wounds and stab wounds. For example, one South African study reported that 75% of penetrating diaphragmatic injuries followed stab wounds.[13] Blunt traumatic mechanisms produce diaphragm trauma less frequently but should raise particular concern for diaphragmatic rupture after significant blunt force transfer, including high-speed motor vehicle collisions (MVCs), auto versus pedestrian collisions, and falls from height. Motor vehicle collisions are the blunt mechanism of injury that produces diaphragmatic injuries most frequently.[11,12,14,15]

Diaphragmatic injuries, especially those that are small, are challenging to diagnose for several reasons. After penetrating trauma, these small injuries tend to be asymptomatic. Computed tomography (CT) is limited in its diagnostic ability for minor diaphragmatic injuries due to the thin nature of the diaphragm and the size of CT scan slices, allowing for small defects to be missed by captured images. It should be underlined that blunt injuries to the diaphragm are much easier to diagnose on CT scan than penetrating injuries to the diaphragm, due to the larger defect size.[16,17] Blunt diaphragmatic injuries also tend to be symptomatic, with patients noting vague but potentially severe pain, which may be felt in the abdomen, chest, or referred to the shoulder. Nonetheless, diagnosis of acute traumatic injury to the diaphragm can be challenging and the need for major trauma society recommendations exists.

A step-by-step approach to the diagnosis and management of acute traumatic diaphragmatic injury is presented here as a clinical decisions algorithm supported by the Western Trauma Association (WTA). Stratifications are made for patient stability, blunt versus penetrating mechanism of injury, and laterality of injury. The algorithm is intended for use in patients with acute full-thickness diaphragmatic injuries, that is, the American Association for the Surgery of Trauma (AAST) Grade II–V diaphragmatic trauma.[18] Patients with diaphragmatic contusions (AAST Grade I injuries) are unlikely to be diagnosed or necessitate intervention.

Western Trauma Association algorithms are drafted by the WTA Algorithms Committee. They are rooted in available data and, especially where data are unavailable or scarce, expert opinion. The process involves extensive revisions by committee members and, ultimately, presentation at the annual WTA meeting for commentary and suggestions by WTA members not on the Algorithms Committee and meeting attendees. The algorithm (Fig. 1) contains letters corresponding to lettered segments within this article. Clinical decisions algorithms should be viewed as suggestions to be complemented by clinical judgment and patient, institutional, or surgeon factors when necessary.

ALGORITHM

A. Initial Screening and Assessment

Trauma patients are evaluated and managed using the standard approach delineated by the American College of Surgeons Advanced Trauma Life Support principles.[19] Primary and

Submitted: June 19, 2024, Revised: November 1, 2024, Accepted: November 17, 2024, Published online: January 28, 2025.

From the Division of Acute Care Surgery, Department of Surgery (M.S., M.J.M.), Los Angeles General Medical Center, Los Angeles; Division of Acute Care Surgery, Department of Surgery (R.C.), Loma Linda University School of Medicine, Loma Linda, California; Division of Acute Care Surgery, Department of Surgery (C.A.C.), University of Florida College of Medicine, Gainesville, Florida; Division of Acute Care Surgery, Department of Surgery (C.F.), University of Maryland School of Medicine, Baltimore, Maryland; Division of Acute Care Surgery, Department of Surgery (J.H.), University of Kansas Medical Center, Kansas City, Kansas; Division of Acute Care Surgery, Department of Surgery (N.K.), University of Arizona College of Medicine-Phoenix, Phoenix, Arizona; Division of Acute Care Surgery, Department of Surgery (M.L.), Methodist Dallas Medical Center, Dallas, Texas; Division of Vascular Surgery and Endovascular Therapy (G.A.M.), Keck Medical Center of USC, Los Angeles, California; Division of Acute Care Surgery, Department of Surgery (L.J.M.), The University of Texas McGovern Medical School-Houston Red Duke Trauma Institute, Memorial Hermann Hospital, Houston, Texas; Division of Acute Care Surgery, Department of Surgery (A.R.P.), Medical University of South Carolina, North Charleston, South Carolina; Division of Acute Care Surgery, Department of Surgery (K.M.S.), Yale School of Medicine, New Haven, Connecticut; UCSF Department of Surgery at Zuckerberg San Francisco General Hospital (R.T.), University of California, San Francisco, San Francisco, California; Division of Acute Care Surgery, Department of Surgery (J.A.W.), St. Joseph's Hospital and Medical Center, Phoenix, Arizona; and Program in Trauma (D.M.S.), University of Maryland School of Medicine, Baltimore, Maryland.

This study was presented at the Western Trauma Association Annual Meeting in Snowmass, CO on February 26, 2024 to March 1, 2024.

Address for correspondence: Morgan Schellenberg, MD, MPH, FRCSC, FACS, Division of Acute Care Surgery, Los Angeles General Medical Center, University of Southern California, 2051 Marengo Street, Inpatient Tower, C5L100, Los Angeles, CA 90033; email: schellenberg.morgan@gmail.com.

DOI: 10.1097/TA.0000000000004554

© 2025 Wolters Kluwer Health, Inc. All rights reserved.

Copyright © 2025 Wolters Kluwer Health, Inc. All rights reserved.

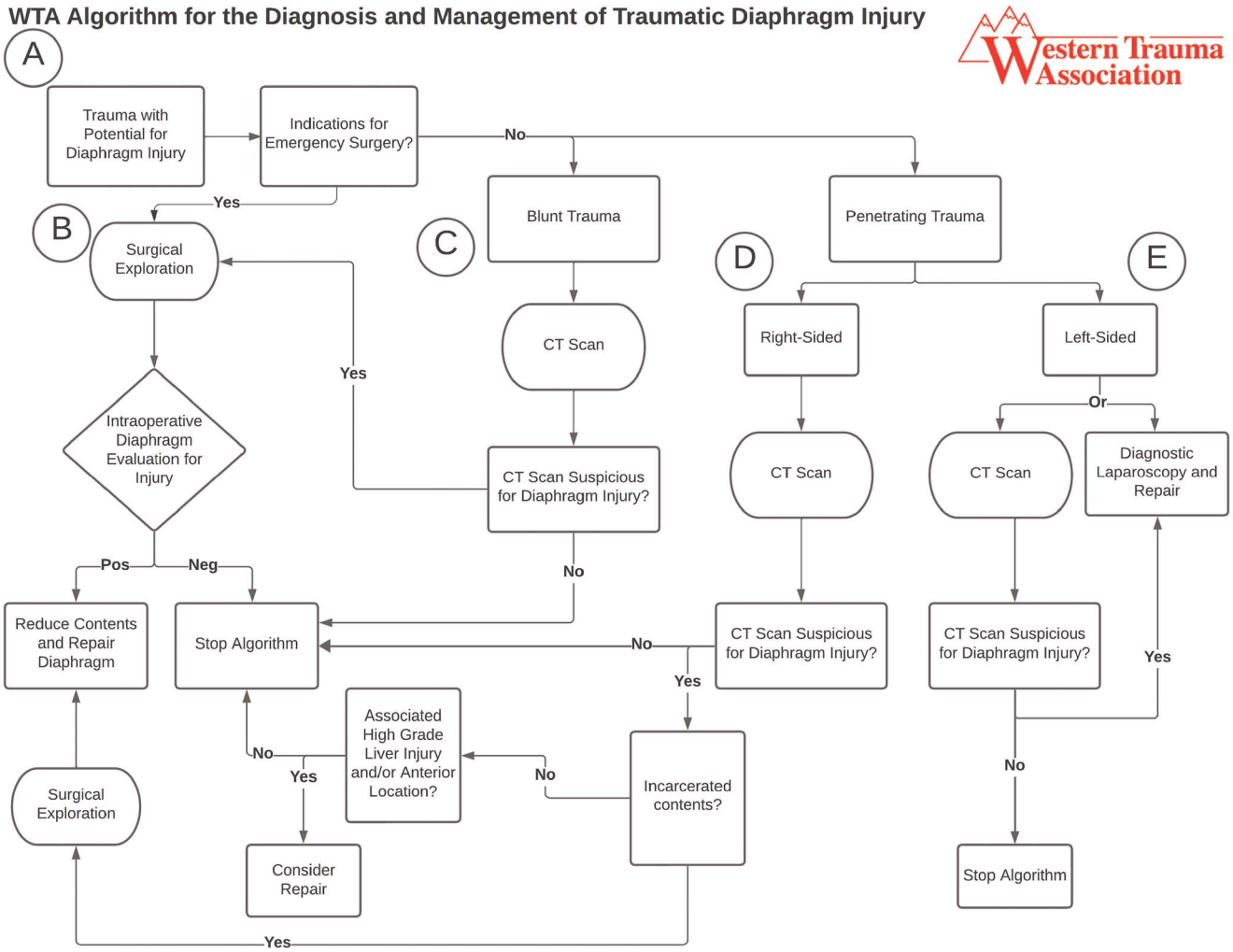

Figure 1. WTA algorithm for the diagnosis and management of traumatic diaphragm injury. Circled letters correspond to lettered article sections.

secondary surveys, as well as mechanism and anatomic location of injury, will provide the screening information necessary for the trauma surgeon or emergency medicine physician to inform concerns for potential acute diaphragmatic trauma based on the mechanism of injury, wounding trajectory, and patient presentation, as described above. Once an at-risk patient is identified, the resultant algorithm is stratified first by the patient's stability, next by blunt versus penetrating mechanism of injury, and lastly by laterality (right- vs. left-sided) for penetrating trauma.

B. Diagnosis and Management of Diaphragmatic Injury in Patients With Indications for Emergency Surgery

As with any trauma patient, hemodynamically unstable patients or those with peritonitis should proceed directly for surgical exploration. It cannot be overemphasized that unstable trauma patients do not belong in the CT scanner. As part of the rapid initial assessment, a chest X-ray is typically indicated. A chest X-ray may show evidence of diaphragmatic rupture, particularly after blunt trauma, with signs ranging from hemidiaphragm elevation to the presence of air-fluid levels within the ipsilateral chest cavity. A normal chest X-ray, however, does not exclude the possibility of a diaphragmatic injury. Penetrating trauma patients with diaphragmatic injury confirmed on CT scan or intraoperatively can be expected to have a normal chest X-ray in up to 60% of cases.[1,20–22] Therefore, intraoperative inspection of the diaphragm for injury is a standard component of every trauma laparotomy.

Surgical exploration is performed next. Direct intraoperative visualization of the diaphragm will permit diaphragmatic injury diagnosis and management. Because the diaphragm can be inspected and repaired from either the chest or abdomen, the surgeon should proceed with diaphragm assessment from within the cavity containing the suspected hemorrhage or other severe injury. For blunt trauma patients, this is typically accomplished through the abdomen. Trauma laparotomy should proceed in the standard fashion, with control of hemorrhage and gastrointestinal tract injury taking precedence over diaphragm repair. For penetrating trauma patients, intraoperative inspection for and repair of diaphragm injuries can occur through the abdomen or chest, depending on the operative cavity.

Technical considerations for diaphragmatic injury repair include reduction of any herniated contents back into their native

© 2025 Wolters Kluwer Health, Inc. All rights reserved.

Copyright © 2025 Wolters Kluwer Health, Inc. All rights reserved.

cavity and careful inspection of these contents for injury before proceeding. The hemithorax of the diaphragmatic injury should be thoroughly irrigated through the diaphragmatic defect before proceeding with repair if enteric contamination is a concern or if there is an associated hemothorax.

Although blunt diaphragmatic injury tends to be much larger and more irregular than penetrating diaphragmatic injury, the principles of repair are similar. Long Allis clamp placement on the defect edges helps deliver the injured tissue into the surgical field and facilitates repair. Once the edges are aligned, a non-absorbable suture[20] on a long needle driver is used to repair the defect. Running versus interrupted sutures and a 1- versus 2-layer repair are left to the surgeon's discretion. Two-layer repairs are not always feasible. Large blunt diaphragm injuries typically tear radially from the esophageal hiatus. Care needs to be taken in repairing such injuries, particularly at the medial aspect around critical structures including the heart, esophagus, and aorta. For this reason, some surgeons find that a medial to lateral approach to repair is best. In posterior blunt diaphragm injuries, there may be little tissue posteriorly to complete the repair. In such cases, the diaphragm may be sutured to the chest wall musculature.[23] In unusual circumstances of large blunt injuries with significant diaphragmatic muscle destruction or avulsion from the chest wall, bridging mesh placement[24] or reapproximation of the diaphragm to the chest wall a few intercostal spaces above the injury may be necessary.

C. Diagnosis and Management of Diaphragmatic Injury in Blunt Trauma Patients Without Indications for Emergency Surgery

The mainstay of the diagnosis of diaphragmatic injury among patients who do not have indications for immediate operative intervention is cross-sectional imaging with CT scanning and intravenous contrast, as would typically be pursued for an acute trauma patient. Intravenous contrast assists in diaphragm assessment as it allows for better delineation of structures from surrounding tissue, rendering abnormalities more conspicuous.[22] Intravenous contrast is especially useful to aid in diagnosis of right-sided diaphragmatic injuries as the liver is similar in attenuation to the diaphragm itself.[25]

Computed tomography scan is most clearly positive for diaphragmatic injury when herniated contents are visualized through such an injury, when the diaphragmatic musculature can be seen to be discontinuous, or when it is implied as a result of a single penetrating trajectory with injuries in both the chest and abdomen. However, there are multiple more subtle signs of injury, including diaphragm hypoattenuation, thickening, or surrounding inflammation. Various signs of diaphragmatic injury have also been described, including the dangling diaphragm and the dependent diaphragmatic signs, and are delineated in detail elsewhere.[20,26–28]

The algorithm diverges by blunt versus penetrating mechanism of injury at this stage due to the differing sensitivities of CT scan in the assessment for diaphragm trauma. After either mechanism, a CT scan has a specificity for diaphragmatic injuries that approaches 100%.[29] The sensitivity of CT scan as a screening investigation for diaphragmatic injury after penetrating trauma is approximately 40%, even with contemporary 256-slice scanners.[29] This may be related to the small size (2–3 cm) of penetrating diaphragmatic injuries,[21] rendering acute herniation of intra-abdominal contents through the defect (a factor that facilitates diagnosis) less likely. In a recent study of 126 patients with confirmed diaphragmatic injuries after penetrating trauma, only 44% had these injuries demonstrated on CT scan.[21] According to a similarly timed metanalysis on blunt diaphragmatic injuries, the sensitivity of CT scan approaches 80%.[30] Secondary signs of diaphragmatic injury, such as stranding or adjacent hematoma, may be present, although their absence does not exclude the possibility of injury. Because of the subtlety of diaphragmatic injuries on CT, it can be helpful to ensure that the diaphragm is closely inspected on all CT views (axial, coronal, and particularly sagittal) by both the radiologist and the trauma surgeon. A diaphragmatic injury missed on initial CT interpretation may subsequently be identified with careful and deliberate attention.

If CT scan reveals a diaphragmatic injury after blunt trauma, the patient should proceed immediately to trauma laparotomy. Diaphragm rupture can be considered a marker of force transfer, reflective of high energy impacts.[31–33] Consequently, and regardless of laterality, reduction of any herniated viscera and direct inspection of intraabdominal contents for potential injury should occur. In other words, even in the absence of other indications on CT scan for an emergent operation, the presence of a diaphragm rupture on either the right or left side should prompt immediate laparotomy. Unlike the repair of chronic diaphragmatic hernias, acute traumatic diaphragmatic hernias are most easily reduced back into their normal anatomic confines through the abdomen. This approach also allows for careful inspection of any herniated contents for ischemia or direct injury, as well as assessment of the abdominopelvic viscera for associated injuries that may have been occult on CT scan. Surgeons with advanced laparoscopic skills may accomplish these steps with a minimally invasive approach in the stable blunt trauma patient.

Because blunt diaphragmatic injuries tend to be large, blunt trauma patients without evidence of diaphragm trauma on CT scan need no further screening to exclude a diaphragmatic injury. However, it is possible that small blunt diaphragmatic injuries, for example from direct laceration related to adjacent rib fractures, are missed with this approach. Preliminary data among blunt trauma patients undergoing surgical rib fixation found that 16% to 20% of patients had diaphragm injuries that were missed by CT scan.[34,35] The clinical relevance of missing these small blunt injuries is unknown, as some small injuries are known to heal spontaneously.[4–6] This is an area in need of further investigation and is discussed below as an area of controversy.

D. Diagnosis and Management of Diaphragmatic Injury in Penetrating Trauma Patients Without Indications for Emergency Surgery: Right-Sided Wounds

Investigations and interventions for penetrating diaphragm injuries are predicated on the laterality of the penetrating thoracoabdominal trauma. The right diaphragm is largely shielded from contact with intra-abdominal viscera by the liver, which is relatively fixed in position. The risk of abdominal organ herniation through a defect caused by a penetrating mechanism in the right diaphragm is consequently much lower than that through an injury in the exposed left diaphragm.

The management of penetrating injuries to the right diaphragm is controversial, due in large part to the paucity of data

© 2025 Wolters Kluwer Health, Inc. All rights reserved.

Copyright © 2025 Wolters Kluwer Health, Inc. All rights reserved.

TABLE 1. Controversies in Acute Traumatic Diaphragm Injury Diagnosis and Management

Controversy	Corresponding Algorithm Section
Potential need for and optimal method of screening for small blunt diaphragm injuries	C
Screening and management of penetrating right-sided diaphragm injuries	D
Potential role for ultrasound in screening for diaphragmatic injury	—

to guide the management decisions for these patients as well as a lack of expert consensus. Indeed, a practice management guideline by the Eastern Association for the Surgery of Trauma highlights the particularly limited literature to guide the optimal management of the diaphragm in hemodynamically normal patients with penetrating right-sided thoracoabdominal trauma.[11] Ultimately, that organization recommends no intervention for the diaphragm in such patients, but again underlines the low quality of evidence available on this subject. In terms of available data, there is no literature to support the need for repair of right-sided penetrating diaphragmatic injuries, even if one is suggested or visualized on CT scan since the liver protects against herniation through a right-sided defect.

Application of surgical principles and common sense suggest that if herniated contents are visualized through such an injury on CT scan, that patient should undergo surgical exploration, reduction of herniated contents, inspection of contents for direct or ischemic injury, and repair of the diaphragmatic defect.

Similarly, repair of right-sided penetrating diaphragmatic injuries may be considered if the injury is anterior or lateral and thus unprotected by the liver. These injuries may be analogous to left-sided injuries, which typically necessitate repair (Section E). There may also be a role for delayed repair of a right-sided penetrating diaphragmatic injury in the context of an associated high-grade liver injury to preempt the development of a biliopleural fistula should a bile leak develop from the injured liver.[36,37] It should be emphasized that this does not suggest that a nonoperative liver injury should be managed with immediate trauma laparotomy for the sole purpose of exposing and repairing the diaphragm. In stable patients with a right-sided penetrating diaphragmatic injury and high-grade liver injury, delayed laparoscopic, thoracoscopic, or robotic diaphragm repair may be helpful if pursued once concerns for hepatic bleeding are resolved. A reactive, as opposed to preemptive, approach to diaphragmatic injury closure among these patients may also be appropriate, reserving intervention for the right diaphragm for only those patients who develop a bilothorax as evidenced by bile visualized within the chest tube. The optimal approach to such patients requires further study.

Although small injuries to the diaphragm will be missed on CT scans, penetrating trauma patients with right-sided thoracoabdominal wounds who lack CT evidence of diaphragmatic injury do not necessitate further screening for diaphragmatic injury.

E. Diagnosis and Management of Diaphragmatic Injury in Penetrating Trauma Patients Without Indications for Emergency Surgery: Left-Sided Wounds

Due to the anatomic vulnerability of the left diaphragm, patients with left-sided thoracoabdominal wounds are generally assessed for diaphragmatic injuries. Penetrating left-sided diaphragmatic injuries typically undergo repair at the index admission to prevent herniation and resultant ischemia or obstruction of abdominal contents through the diaphragmatic injury over time. After initial assessment in the trauma bay, patients with left-sided penetrating trauma who have no indications for emergent surgery may proceed either to CT scan or directly for diagnostic laparoscopy.

As discussed previously, CT scan is a useful but inconclusive screening investigation in this population. Most importantly, CT scan cannot exclude a diaphragmatic injury due to its low sensitivity for detection of these injuries. If CT scan demonstrates an extracavitary wounding trajectory or a trajectory that is clearly away from the diaphragm, the CT scan is not suspicious for injury to the diaphragm and the evaluation for potential diaphragmatic injury is therefore complete. Otherwise, the CT scan should be followed up with a delayed diagnostic laparoscopy to assess and repair the diaphragm after a hollow viscus injury has been excluded clinically via a period of close observation, although there is a lack of consensus regarding this approach. Based on the selective nonoperative management literature among patients with penetrating abdominal trauma, this delayed diagnostic laparoscopy should take place 24 hours after the initial trauma as this is the length of time required to clinically exclude a hollow viscus injury.[38–40] Laparoscopy is preferred over laparotomy for this purpose for its minimally invasive nature, the associated reduction in hospital and intensive care unit lengths of stay,[41,42] and mitigation of downstream consequences of laparotomy, including ventral hernias and adhesive small bowel obstructions. Robotic repair may be similarly beneficial, although this has not yet been studied for this purpose beyond case reports.[43] Any form of surgical intervention should be carefully considered in terms of risks and benefits to the patient. Although laparoscopy is minimally invasive, it remains a surgical procedure that should not be undertaken needlessly.

Alternatively, stable patients with penetrating left-sided thoracoabdominal trauma may be taken immediately for diagnostic laparoscopy and repair of any identified injuries without CT scanning.[44] It should be emphasized that if immediate laparoscopy is pursued, the surgeon must have the laparoscopic skills to exclude bowel injury intraoperatively with a minimally invasive approach. The immediate laparoscopy pathway eliminates the cross-sectional imaging step but will incur more nontherapeutic operations as the CT pathway will eliminate the need for laparoscopy in patients with trajectories that are extracavitary and those that are remote from the diaphragm. The immediate laparoscopy pathway also raises the possibility for missed hollow viscus injuries, and therefore careful consideration of surgeon skillset must be made when selecting an approach.

© 2025 Wolters Kluwer Health, Inc. All rights reserved.

Copyright © 2025 Wolters Kluwer Health, Inc. All rights reserved.

OTHER AREAS OF CONTROVERSY

There are several areas of ongoing controversy in the diagnosis and management of acute traumatic injury to the diaphragm, which are described in the above sections of the Algorithm and summarized in Table 1. Three are worthy of further highlighting here. The most notable relates to the need for screening and repair of diaphragmatic injuries following penetrating trauma to the right thoracoabdomen, which is the most controversial and least data-driven aspect of this algorithm. There are no data on which of these patients, if any, should be treated as left-sided thoracoabdominal penetrating trauma patients. Specifically, the need for repair of known injuries diagnosed on CT scans is unclear; the impact of associated liver injuries is unknown; the effect of anatomic location of injury on the need for repair is obscure; and as a consequence, the indications for screening or repair in this population is controversial. At present, clinical experience, surgical principles, and expert opinion form the basis for the recommendations among this patient subset. It should be underlined that there were differing opinions among the committee and membership, with some advocating for repair of all or none of the penetrating right-sided diaphragmatic injuries diagnosed on CT scan.

Next, it is possible that small blunt diaphragmatic injuries are missed on CT scan, as is known to be true for penetrating trauma. These smaller injuries may result from laceration from adjacent rib fractures. Two studies of blunt trauma patients undergoing surgical rib fixation lend weight to this theory. In these studies, the diaphragm was routinely inspected intraoperatively during rib fracture stabilization. These authors found the rate of diaphragm injury missed on CT scan to be 16% to 20% in this subpopulation.[34,35] Although this percentage is substantial, it should be emphasized that the clinical implication of these findings is presently unknown. Further work is needed to elicit the patient population at risk for clinically significant small blunt diaphragmatic injuries so that an approach to screening and intervention can be established.

Last, ultrasound has been investigated to a limited extent for diaphragm assessment in the acute trauma patient. In one such study, ultrasound demonstrated sensitivity of 50% and specificity of 100% in detecting diaphragmatic injuries after penetrating trauma, using intraoperative visualization as the gold standard.[45] For a screening investigation, a sensitivity of 50% is inadequate. However, as many trauma investigations shift to the bedside and toward ultrasonography as a diagnostic test of choice, this may evolve with time, experience, and further study.

SUMMARY

Acute traumatic injuries to the diaphragm remain difficult to diagnose and manage. This is due to limitations in noninvasive diagnostic methods and a lack of definition of specific patient populations who stand to benefit from diaphragmatic injury screening and closure among those with CT-occult injuries.

In general, concern for diaphragmatic injury should arise after high-energy blunt trauma mechanisms and penetrating thoracoabdominal trauma. Patients with indications for emergent surgical exploration should undergo direct intraoperative visualization of the diaphragm, with repair of any identified injuries after reduction of any herniated contents. From there, the algorithm diverges according to blunt and penetrating trauma mechanisms due to the increased ability of CT scan to diagnose large as opposed to small injuries of the diaphragm. Patients with blunt diaphragmatic injury on CT necessitate repair and otherwise need no further screening for CT-occult diaphragmatic injury.

Penetrating trauma patients with visualized or implied injuries to the diaphragm are managed according to laterality. Left-sided thoracoabdominal injuries generally need screening prior to hospital discharge with a diagnostic laparoscopy and repair of any identified injuries. Management of right-sided injuries are controversial and lacking in data regarding which, if any, ought to be repaired.

AUTHORSHIP

M.S., R.C., C.A.C., C.F., J.H., N.K., M.L., M.J.M., G.A.M., L.J.M., A.R.P., K.M.S., R.T., J.A.W., D.M.S. participated in the conception and study design. M.S. participated in the literature review. M.S. participated in the data acquisition. M.S., R.C., C.A.C., C.F., J.H., N.K., M.L., M.J.M., G.A.M., L.J.M., A.R.P., K.M.S., R.T., J.A.W., D.M.S. participated in the data analysis and interpretation. M.S., D.M.S. participated in the drafting of the article. R.C., C.A.C., C.F., J.H., N.K., M.L., M.J.M., G.A.M., L.J.M., A.R.P., K.M.S., R.T., J.A.W. participated in the critical revision.

DISCLOSURE

Author disclosure forms have been supplied and are provided as Supplemental Digital Content (http://links.lww.com/TA/E222).

REFERENCES

1. Hammer MM, Raptis DA, Mellnick VM, Bhalla S, Raptis CA. Traumatic injuries of the diaphragm: overview of imaging findings and diagnosis. *Abdom Radiol (NY)*. 2017;42(4):1020–1027.
2. Reber PU, Schmied B, Seiler CA, Baer HU, Patel AG, Buchler MW. Missed diaphragmatic injuries and their long-term sequelae. *J Trauma*. 1998;44:183–188.
3. Guevara-Kissel MF, Gumbs S, Andrade J, Donaldson B. Strangulated gastric hernia following a missed traumatic diaphragmatic injury: a case report. *Cureus*. 2023;15(9):e46273.
4. LA-Falce TS, Martini Filho D, Botter M, Saad Junior R. Natural evolution of perforating wounds of 30% extension of the left diaphragm and the anatomopathological characteristics of its healing. Experimental study. *Rev Col Bras Cir*. 2022;49:e20223162.
5. Gamblin TC, Wall CE Jr., Morgan JH 3rd, Erickson DJ, Dalton ML, Ashley DW. The natural history of untreated penetrating diaphragm injury: an animal model. *J Trauma*. 2004;57(5):989–992.
6. Zierold D, Perlstein J, Weidman ER, Wiedeman JE. Penetrating trauma to the diaphragm: natural history and ultrasonographic characteristics of untreated injury in a pig model. *Arch Surg*. 2001;136(1):32–37.
7. Thiam O, Konate I, Gueye ML, Toure AO, Seck M, Cisse M, et al. Traumatic diaphragmatic injuries: epidemiological, diagnostic and therapeutic aspects. *Springerplus*. 2016;5(1):1614.
8. Sprunt JM, Brown CV, Reifsnyder AC, Shestopalov AV, Ali S, Fielder WD. Computed tomography to diagnose blunt diaphragm injuries: not ready for prime time. *Am Surg*. 2014;80(11):1124–1127.
9. Epstein LI, Lempke RE. Rupture of right hemi diaphragm due to blunt trauma. *J Trauma*. 1968;21:35–38.
10. Taş İ, Yiğit E. Analysis of traumatic acute diaphragmatic injuries. *Singapore Med J*. 2023; Epub ahead of print.
11. McDonald AA, Robinson BRH, Alarcon L, Bosarge PL, Dorion H, Haut ER, et al. Evaluation and management of traumatic diaphragmatic injuries: a practice management guideline from the Eastern Association for the Surgery of Trauma. *J Trauma Acute Care Surg*. 2018;85(1):198–207.
12. Fair KA, Gordon NT, Barbosa RR, Rowell SE, Watters JM, Schreiber MA. Traumatic diaphragmatic injury in the American College of Surgeons National Trauma Data Bank: a new examination of a rare diagnosis. *Am J Surg*. 2015;209:864–868.

© 2025 Wolters Kluwer Health, Inc. All rights reserved.

Copyright © 2025 Wolters Kluwer Health, Inc. All rights reserved.

13. D'Souza N, Clarke D, Laing G. Prevalence, management and outcome of traumatic diaphragm injuries managed by the Pietermaritzburg Metropolitan Trauma Service. *Ann R Coll Surg Engl*. 2017;99(5):394–401.
14. Hogarty J, Jassal K, Ravintharan N, Adhami M, Yeung M, Clements W, et al. Twenty-year perspective on blunt traumatic diaphragmatic injury in level 1 trauma centre: early versus delayed diagnosis injury patterns and outcomes. *Emerg Med Australas*. 2023;35(5):842–848.
15. Kuo IM, Liao CH, Hsin MC, Kang SC, Wang SY, Ooyang CH, et al. Blunt diaphragmatic rupture—a rare but challenging entity in thoracoabdominal trauma. *Am J Emerg Med*. 2012;30(6):919–924.
16. Sliker CW. Imaging of diaphragm injuries. *Radiol Clin North Am*. 2006; 44(2):199–211.
17. Nchimi A, Szapiro D, Ghaye B, Willems V, Khamis J, Haquet L, Noukoua C, Dondelinger RF. Helical CT of blunt diaphragmatic rupture. *Am J Roentgenol*. 2005;184(1):24–30.
18. Moore EE, Malangoni MA, Cogbill TH, Shackford SR, Champion HR, Jurkovich GJ, et al. Organ injury scaling. IV: thoracic vascular, lung, cardiac, and diaphragm. *J Trauma*. 1994;36(3):299–300.
19. American College of Surgeons. Advanced Trauma Life Support. 2023. Accessed December 30, 2023. Available at https://www.facs.org/quality-programs/trauma/education/advanced-trauma-life-support/?page=1.
20. Giuffrida M, Perrone G, Abu-Zidan F, Agnoletti V, Ansaloni L, Baiocchi GL, et al. Management of complicated diaphragmatic hernia in the acute setting: a WSES position paper. *World J Emerg Surg*. 2023;18(1):43.
21. Cremonini C, Lewis MR, Jakob D, Benjamin ER, Chiarugi M, Demetriades D. Diagnosing penetrating diaphragmatic injuries: CT scan is valuable but not reliable. *Injury*. 2022;53(1):116–121.
22. Bonatti M, Lombardo F, Vezzali N, Zamboni GA, Bonatti G. Blunt diaphragmatic lesions: imaging findings and pitfalls. *World J Radiol*. 2016;8(10): 819–828.
23. Kamiyoshihara M, Igai H, Kawatani N, Ibe T. A minimally invasive technique for stabilizing the diaphragm on the thoracic wall after blunt chest trauma: the "lifting-up method". *Surg Today*. 2016;46(7):872–875.
24. Ercan M, Aziret M, Karaman K, Bostancı B, Akoğlu M. Dual mesh repair for a large diaphragmatic hernia defect: an unusual case report. *Int J Surg Case Rep*. 2016;28:266–269.
25. Cardoso LF, Gonçalves MVC, Machado CJ, Resende V, Fernandes MP, Pastore-Neto M, et al. Retrospective analysis of 103 diaphragmatic injuries in patients operated in a trauma center. *Rev Col Bras Cir*. 2017;44(3): 245–251.
26. Gmachowska A, Pacho R, Anysz-Grodzicka A, Bakoń L, Gorycka M, Jakuczun W, Patkowski W. The role of computed tomography in the diagnostics of diaphragmatic injury after blunt thoraco-abdominal trauma. *Pol J Radiol*. 2016;81:522–528.
27. Desser TS, Edwards B, Hunt S, Rosenberg J, Purtill MA, Jeffrey RB. The dangling diaphragm sign: sensitivity and comparison with existing CT signs of blunt traumatic diaphragmatic rupture. *Emerg Radiol*. 2010;17:37–44.
28. Cantwell CP. The dependent viscera sign. *Radiology*. 2006;238:252–253.
29. Uhlich R, Kerby JD, Bosarge P, Hu P. Diagnosis of diaphragm injuries using modern 256-slice CT scanners: too early to abandon operative exploration. *Trauma Surg Acute Care Open*. 2018;3(1):e000251.
30. Reitano E, Cioffi SPB, Airoldi C, Chiara O, La Greca G, Cimbanassi S. Current trends in the diagnosis and management of traumatic diaphragmatic injuries: a systematic review and a diagnostic accuracy meta-analysis of blunt trauma. *Injury*. 2022;53(11):3586–3595.
31. Kruger VF, Calderan TAR, Hirano ES, Fraga GP. The silent threat: a retrospective study of right-sided traumatic diaphragmatic hernias in a university hospital. *Turk J Surg*. 2023;39(4):365–372.
32. Schurr LA, Thiedemann C, Alt V, Schlitt HJ, Götz M, Riedl M, et al. Diaphragmatic injuries among severely injured patients (ISS ≥ 16)—an indicator of injury pattern and severity of abdominal trauma. *Medicina (Kaunas)*. 2022;58(11):1596.
33. Kumar S, Pol M, Mishra B, Sagar S, Singhal M, Misra MC, Gupta A. Traumatic diaphragmatic injury: a marker of serious injury challenging trauma surgeons. *Indian J Surg*. 2015;77(Suppl 2):666–669.
34. Murfee JR, Pardue KE, Farley P, Polite NM, Mbaka MI, Bright AC, et al. Unexpected diaphragmatic hernia among patients undergoing video-assisted thoracic surgery for internal fixation of rib fractures. *Am Surg*. 2022;88(4): 618–622.
35. Wemeijer TM, Hogeboom W, Steenvoorde P, Withaar DS, de Groot R. Missed injuries in trauma patients: the value of a diagnostic thoracotomy or thoracoscopy during surgical stabilisation of rib fractures. *Ir J Med Sci*. 2022;191(3):1285–1289.
36. Schellenberg M, Ball CG, Owattanapanich N, Emigh B, Murphy PB, Moffat B, Mador B, Beckett A, Lee J, Joos E, Minor S, Strickland M, Inaba K, TAC Bile Leaks Study Group. Diagnosis and management of bile leaks after severe liver injury: a Trauma Association of Canada multicenter study. *J Trauma Acute Care Surg*. 2022;93(6):813–820.
37. Streith L, Silverberg J, Kirkpatrick AW, Hameed SM, Bathe OF, Ball CG. Optimal treatments for hepato-pancreato-biliary trauma in severely injured patients: a narrative scoping review. *Can J Surg*. 2020;63(5):E431–E434.
38. Owattanapanich N, Cremonini C, Schellenberg MA, Matsushima K, Lewis MR, Lam L, et al. Prospective evaluation of the selective nonoperative management of abdominal stab wounds: when is it safe to discharge? *J Trauma Acute Care Surg*. 2022;93(5):639–643.
39. Inaba K, Branco BC, Moe D, Barmparas G, Okoye O, Lam L, et al. Prospective evaluation of selective nonoperative management of torso gunshot wounds: when is it safe to discharge? *J Trauma Acute Care Surg*. 2012; 72(4):884–891.
40. Inaba K, Barmparas G, Foster A, Talving P, David JS, Green D, et al. Selective nonoperative management of torso gunshot wounds: when is it safe to discharge? *J Trauma*. 2010;68:1301–1304.
41. Obaid O, Hammad A, Bible L, Ditillo M, Castanon L, Douglas M, et al. Open versus laparoscopic repair of traumatic diaphragmatic injury: a nationwide propensity-matched analysis. *J Surg Res*. 2021;268:452–458.
42. Chaudhry HH, Grigorian A, Lekawa ME, Dolich MO, Nguyen NT, Smith BR, et al. Decreased length of stay after laparoscopic diaphragm repair for isolated diaphragm injury after penetrating trauma. *Am Surg*. 2020;86(5): 493–498.
43. Hargrave A, Przeslawski C, Solomon Schnurr CA, Jamil K. Robotic repair of acute traumatic diaphragmatic injury from an abdominal approach: a case report. *Cureus*. 2024;16(8):e68335.
44. D'Souza N, Bruce JL, Clarke DL, Laing GL. Laparoscopy for occult left-sided diaphragm injury following penetrating thoracoabdominal trauma is both diagnostic and therapeutic. *Surg Laparosc Endosc Percutan Tech*. 2016;26(1):e5–e8.
45. Sharifi A, Kasraianfard A, Chavoshi Khamneh A, Kanani S, Aldarraji M, Seif-Rabiei MA, et al. Value of ultrasonography in detection of diaphragmatic injuries following thoracoabdominal penetrating trauma: a diagnostic accuracy study. *Arch Acad Emerg Med*. 2019;7(1):e45.

© 2025 Wolters Kluwer Health, Inc. All rights reserved.

Copyright © 2025 Wolters Kluwer Health, Inc. All rights reserved.